

International Board Certification in Dermatopathology

A Worldwide Effort to Raise Standards in Dermatopathology

Helmut Kerl, MD,¹ Lorenzo Cerroni, MD,¹ Günter Burg, MD,² Rino Cerio, MD,³
Harald Gollnick, MD,⁴ Heinz Kutzner, MD,⁵ and Omar Sanguenza, MD⁶

Key Words: Dermatopathology; International Board Certification; Standards; Future

DOI: 10.1309/YG1V54UUQ6PBK8NH

On December 11, 2004, the second International Board Certification in Dermatopathology (Diploma of Dermatopathology), organized by the International Board of Dermatopathology under the auspices of the International Committee for Dermatopathology, was held in Frankfurt/Main, Germany. The examination was sponsored by the International Society of Dermatopathology, the European Society for Dermatopathology, and the Ibero-Latin-American Society of Dermatopathology and was open to dermatologists and pathologists from all countries in the world. The International Board of Dermatopathology **Image 1** was chaired by Helmut Kerl (president, International Committee for Dermatopathology) and included Günter Burg (general secretary, International Committee for Dermatopathology), Rino Cerio (president, European Society for Dermatopathology), Lorenzo Cerroni (president, Austrian Society of Dermatopathology; past-president, International Society of Dermatopathology), Bernard Cribier (Strasbourg, France; secretary, European Society for Dermatopathology), Harald Gollnick (president, Union Européenne des Médecins Spécialistes [UEMS], Section of Dermatology and Venereology; president, German Society of Dermatology), Philip E. LeBoit (San Francisco, CA; editor-in-chief, *American Journal of Dermatopathology*), Omar Sanguenza (Winston-Salem, NC; president, International Society of Dermatopathology; president, Ibero-Latin-American Society of Dermatopathology), Heinz Kutzner (representative for dermatopathology, German League of Dermatology), and Bruce R. Smoller (Little Rock, AR; past-president, American Society of Dermatopathology). Maureen Walsh (Belfast, Northern Ireland; chief examiner for the Diploma in Dermatopathology, Royal College of

Pathologists, London, England) and Dirk Ruiter (Nijmegen, the Netherlands; president, UEMS, Section of Pathology) represented the Royal College of Pathologists and the UEMS Section of Pathology, respectively. Roland Kaufmann and especially Manfred Wolter took care of the local organization, providing the venue, the microscopes, and particularly the very friendly atmosphere that characterized the event.

Thirty-four candidates **Image 2** from 15 countries (Belgium, 7; Germany, 6; Italy, 3; England, 3; Austria, 2; Hungary, 2; Spain, 2; United States, 2; France, 1; Iran, 1; Israel, 1; the Netherlands, 1; Portugal, 1; Saudi Arabia, 1; South Korea, 1) gathered in Frankfurt to sit for the examination, which was structured in 3 main parts. The first consisted of 56 written questions **Table 1**, followed by the second in which 28 images (immunohistologic or clinical images) were projected on a screen **Image 3** and **Image 4**. In the last part, 70 histopathologic sections of inflammatory and neoplastic skin conditions were reviewed **Image 5** and **Image 6**. The examination was based on multiple-choice or short-answer questions and lasted the whole day (9:00 AM to 5:30 PM), with a short interruption for lunch.

The first examination in Frankfurt in 2003¹⁻³ was a milestone in the history of dermatopathology in Europe and, indeed, worldwide. For the first time on the “old continent,” there was an attempt to raise the standards of dermatopathology with the assessment of individual competence on the basis of a formal examination. In addition, for the first time, such an examination was not limited to members of a specific medical society and/or residents of a given country but was open to every dermatologist and pathologist worldwide (with the proviso that specific requirements concerning training in



Image 1 Members of the International Board of Dermatopathology present in Frankfurt, Germany, in 2004. Left to right: L. Cerroni, H. Kutzner, H. Kerl, H. Gollnick, Maureen Walsh (chief examiner for the Diploma in Dermatopathology, Royal College of Pathologists), R. Kaufmann (chairman, Department of Dermatology, University of Frankfurt/Main), G. Burg, O. Sanguenza, M. Wolter (local organization).

dermatopathology were fulfilled). In other words, not only was the aim of the examination to raise the level of quality in dermatopathology, but the examination also was without boundaries, thus being one of the first attempts at international



Image 2 International Board Certification in Dermatopathology, 2004: 34 candidates from 15 countries took the examination in Frankfurt, Germany.

certification in the history of medicine. This also was reflected in the composition of the Examination Committee, which included leading persons from most international dermatopathology societies worldwide.

The second examination in Frankfurt in 2004 was structured in a similar manner. The high number of candidates coming from so many disparate countries in Europe, North America, the Middle East, and Asia clearly confirmed the

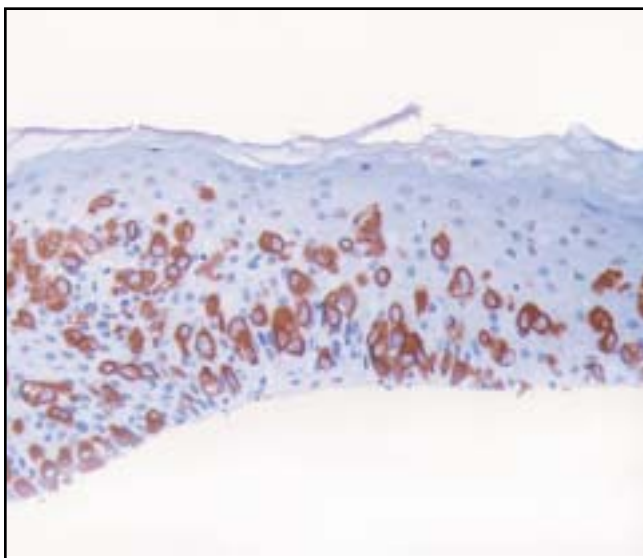


Image 3 Examination, part 2 (images). The question was as follows: The pagetoid cells in this lesion from the genital region are identified by: (A) Cytokeratin 5; (B) Cytokeratin 7; (C) Cytokeratin 20; (D) Cytokeratin 10. The correct answer (B) was given by 28/34 candidates.

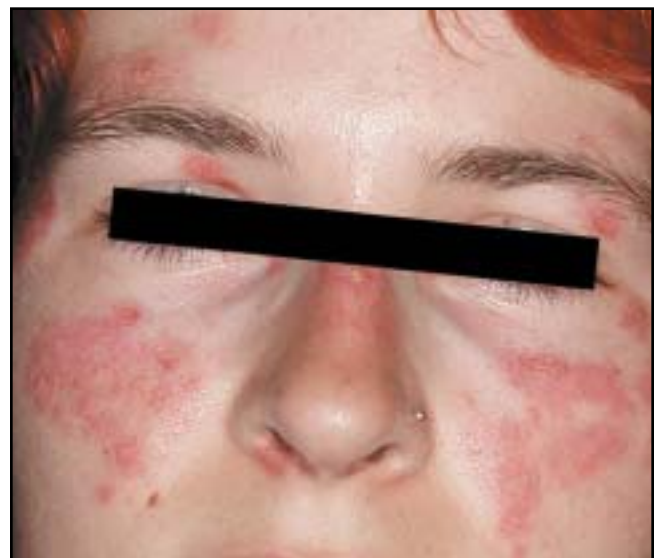

Image 4 Examination, part 2 (images). The question was as follows: Name the clinical diagnosis. The correct answer (lupus erythematosus) was given by 33/34 candidates.

need for the examination and its international nature. The vast majority of the candidates identified Frankfurt as an optimal location for the examination and found the structure of the examination itself adequate. For the future, in most countries many important goals are left to be achieved^{4,5}:

1. *The need for full-time professional dermatopathologists with special expertise and without any other obligations.*

In most countries of the world, dermatopathology is not performed on a full-time basis but rather by dermatologists or pathologists who spend only a limited amount of time doing it, thus lacking the necessary experience.

Table 1
Examples of Examination Questions in Part 1*

25. Bullous impetigo (impetigo contagiosa) may show a histologic pattern similar to:
 A. Pemphigus foliaceus
 B. Lichen planus pemphigoides
 C. Dermatitis herpetiformis Duhring
 D. Bullous systemic lupus erythematosus
48. The second most powerful histologic prognostic indicator (AJCC-criteria) in patients with stages I and II melanoma is:
 A. Breslow thickness
 B. Mitotic rate
 C. Ulceration
 D. Regression

* Written, multiple-choice items. Correct answers were as follows: 25, A (33/34 candidates gave the correct answer); 48, C (25/34 candidates gave the correct answer).

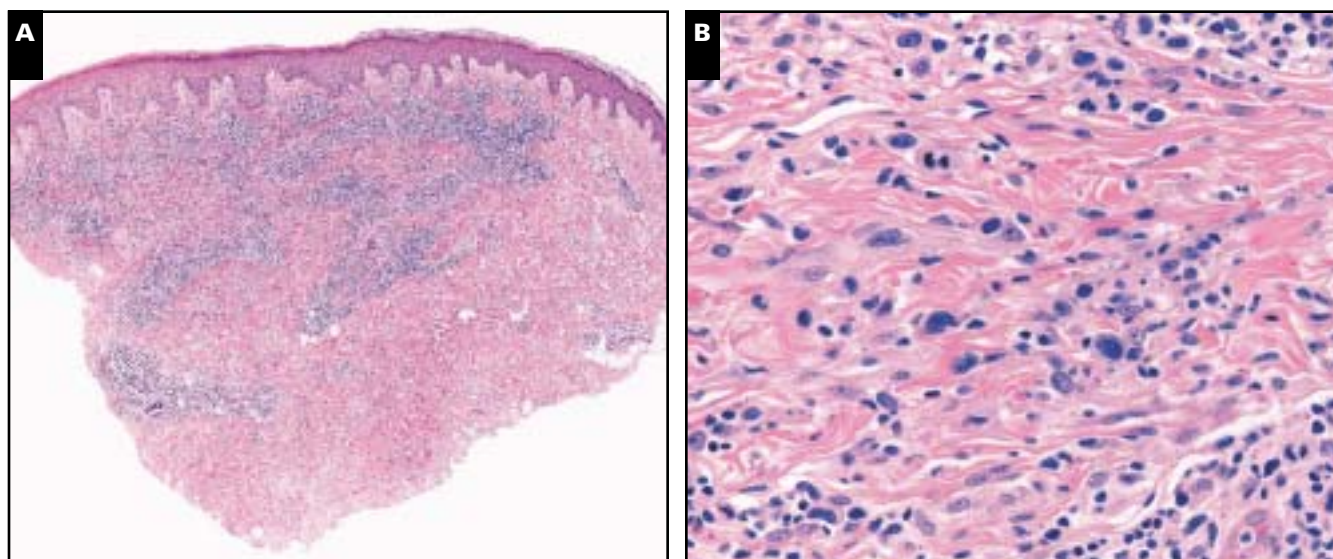


Image 5 **A** and **B**, Examination, part 3 (histopathologic slides). The question was as follows: 45-year-old woman. Multiple papules and small nodules, especially on both legs. (A) Drug eruption; (B) Lymphomatoid papulosis; (C) Histiocytosis X; (D) Persistent scabies. The correct answer (B) was given by 33/34 candidates.

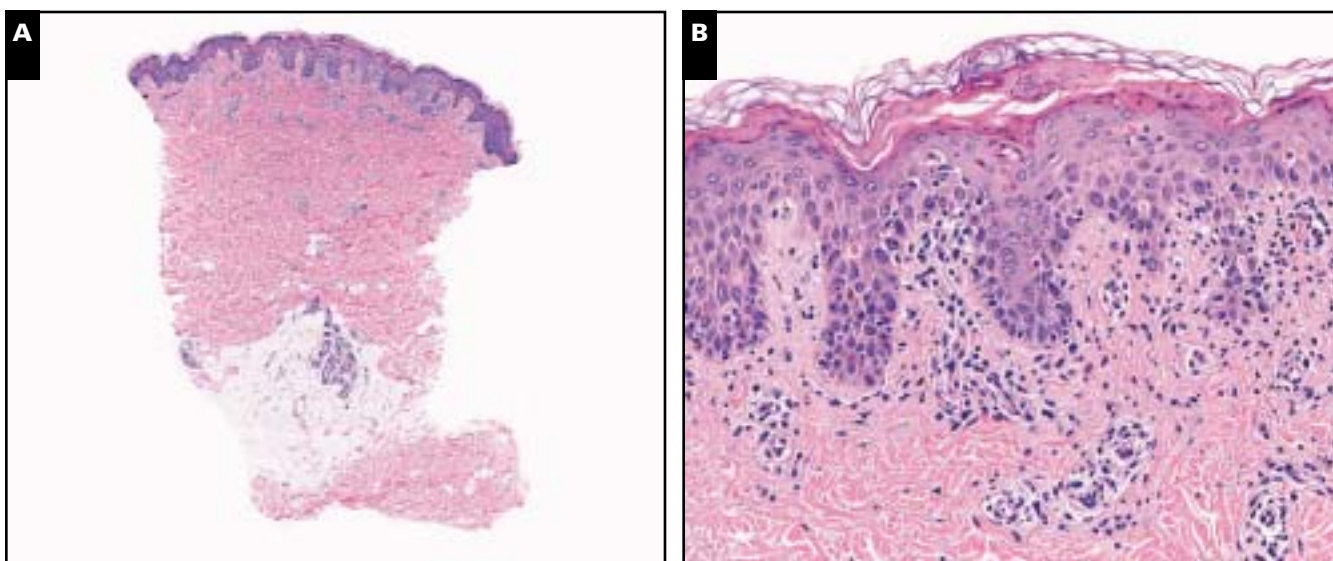


Image 6 **A** and **B**, Examination, part 3 (histopathologic slides). The question was as follows: 8-year-old girl. Sudden onset of erythematous papules on the trunk. The correct answer (pityriasis lichenoides et varioliformis acuta) was given by 22/34 candidates.

2. *The introduction of a curriculum for specialty training in dermatopathology.* At present, such a curriculum is available in only a few countries.
3. *The identification of training centers and the establishment of regulations for accreditation of training programs.* Dermatopathologists should be trained at a high level of quality in centers with vast experience and teaching facilities. Unfortunately, precise regulations for the identification of training centers are lacking in most countries.
4. *The development of a program for residency education in dermatopathology (in both dermatology and pathology residency programs).* All residents in dermatology or pathology should be trained in dermatopathology during their residency.
5. *The layout of an economic basis for dermatopathology.* With the exception of a few countries such as the United States and Germany, students (dermatologists) in dermatopathology are denied professional opportunities outside academic centers. Especially residents in dermatology are attracted, therefore, by more rewarding subspecialties.
6. *The arrangement of an academic basis for dermatopathology.* At present in many countries, those practicing dermatopathology at academic centers are denied possibilities of high academic careers. The introduction of departments for dermatopathology would clearly improve the academic backgrounds of dermatopathology in Europe and other countries, in the same way as it did in the United States.

The third International Board Certification in Dermato-pathology will be organized on December 10, 2005, in Frankfurt/Main, Germany (www.icdpath.org).

From the ¹Department of Dermatology, Medical University of Graz, Graz, Austria; ²Department of Dermatology, University Hospital Zurich, Zurich, Switzerland; ³Department of Dermatology, Royal London University Hospital, London, England; ⁴Department of Dermatology, Otto-von-Guericke-University Magdeburg, Magdeburg, Germany; ⁵Dermatohistology Laboratory, Friedrichshafen, Germany; and ⁶Departments of Pathology and Dermatology, Wake Forest University School of Medicine, Winston-Salem, NC.

Address reprint requests to Dr Kerl: Dept of Dermatology, Medical University of Graz, Auenbruggerplatz, 8, A-8036 Graz, Austria.

References

1. Kerl H, Cerroni L, Burg G, et al. International board certification in dermatopathology: paving the way for the future. *Am J Dermatopathol*. 2004;26:439-440.
2. Kerl H, Cerroni L, Burg G, et al. International board certification in dermatopathology: paving the way for the future. *J Cutan Pathol*. 2004;31:683-685.
3. Kerl H, Cerroni L, Burg G, et al. International board certification in dermatopathology: paving the way for the future. *JDDG*. 2004;2:476-477.
4. Kerl H. Dermatopathology in Europe. *Arch Dermatol*. 1999;135:21-24.
5. Kerl H. Über die Situation der Dermatopathologie in Europa. *Pathologe*. 2002;23:1-3.